

Case Report

A massive dose of allogeneic platelet gel for wound hemostatic therapy on patients with giant thoracic aortic aneurysm: report of 2 cases

Jianjun Wu^{1△}, Bin Jiang^{2△}, Renxue Xiang¹, Ronghui Shi¹, Changsheng He¹, Kang Yang², Xin Cui³, Shuming Zhao^{1*}

¹ Department of Blood Transfusion, GuiQian International General Hospital, Guiyang, Guizhou 550018, China;

² Department of Cardiothoracic Surgery, GuiQian International General Hospital, Guiyang, Guizhou 550018, China;

³ Guizhou Province Blood Center, Guiyang, Guizhou 550002, China.

ABSTRACT

Autologous platelet-rich plasma (PRP) or platelet gel (PG) has been widely used in clinical treatment. Allogeneic PRP or PG may also become a safe and effective alternative method. In this study, two cases with giant thoracic aortic aneurysm were reported where massive doses of allogeneic PG were used to spray the thoracic aortic aneurysm wall suture wrapped in artificial blood vessels, tumors blood vessel wall anastomotic site, and incision site of surgical operation. The volumes of 220 mL and 250 mL PG were applied on two patients respectively, to clot bleeding and decrease the mediastinal and pericardial drainage days after operation. The drainage tubes were pulled out on the 4th day after operation. The patients were transferred from ICU to a cardiothoracic surgery ward on the 4th and 5th day respectively. This study suggests that allogeneic platelet concentrate, as a source of PRP to prepare PG, may be used to promote and help the clotting and wound healing on surgical operation.

Keywords: allogeneic platelet, platelet-rich plasma, platelet gel, thoracic aortic aneurysms

INTRODUCTION

Platelets are mainly used for transfusions in patients with thrombocytopenia and platelet dysfunction. In recent years, with advances of platelet function, platelets have been found, in addition to hemostasis and maintaining the integrity of vascular endothelium, to have anti-inflammatory effects, and are able to promote tissue growth and wound repair. In addition to conventional platelet transfusion, platelets, or their

derivatives have gradually been developed to expand their related fields, such as autologous platelet-rich plasma (PRP) and autologous platelet gel (PG), for the treatment of surgical trauma and inflammation^[1–5]. Lyophilized platelets and frozen platelet preparations have also been used for autologous transfusion in the military field or for special patients. Allogeneic platelets have also been used in patients with traumatic wounds or surgical operations^[6–9]. The application of massive doses of allogeneic PRP or PG

*Corresponding to: Shuming Zhao, Department of Blood Transfusion, GuiQian International General Hospital, No 1, Dongfeng Street, Wudang District, Guiyang, Guizhou 550018, China. E-mail: shumingzhao123@qq.com.

△These authors contributed equally to this work.

Conflict of interests: The authors declared no conflict of interests.

was relatively rare. Here, this paper reported the two cases of giant thoracic aortic aneurysm successfully treated with massive doses of allogeneic PG.

CASE REPORT

Difficulty in collecting autologous platelets was experienced in both patients. After consultation and discussion, the patients and their families agreed and signed informed consent for the transfusion. The study was approved by the ethical committee of the hospital. The apheresis platelet concentrates were obtained from Guizhou Province Blood Center.

Case 1

Patient 1, female, 67 years old, was admitted to the department of cardiothoracic surgery on August 13, 2020, due to "intermittent chest tightness with dizziness and headache for more than 10 years, aggravating for more than 10 days". The preoperative diagnoses were ascending thoracic aortic aneurysm with chronic aortic dissection, aortic insufficiency, hypertension grade 3 (very high risk), and cardiac function grade II - III (NYHA grade).

The operation was performed by Bentall method. Under total anesthesia and deep hypothermic circulatory arrest, the ascending aorta was replaced with aortic valve prosthesis. The preparation and application of platelet gel was performed according to the routine operation method. We used standard allogeneic apheresis platelet that was ABO and RhD matched, serologically HIV, HBV, HCV and TP-negative, and leukocyte depleted. A dose of standard single donor apheresis platelets as PRP was stored in a plastic bag designed for platelet storage and placed on an automatic agitator for up to five days. A bag of allogeneic apheresis platelets with a volume of 220 mL was obtained. Thrombin and calcium gluconate were prepared in sterile condition before the operation. In the operating room, 500 units of thrombin lyophilized powder (Changchun Leiyunshang Pharmaceutical Co., Ltd. Batch No.: 201900802) dissolved in 10 mL of 10% calcium gluconate (Huarun Shuanghe Limin Pharmaceutical (Ji'nan) Co., Ltd., Batch No.: 20020511) was mixed with PRP at 1 : 10 ratio to activate the platelets and promote fibrinogen aggregation, which usually takes about 20 -30 seconds to form gel. After Bentall's operation and spontaneous heart rate recovery, the thoracic aortic aneurysm wall was sutured and wrapped on the artificial blood vessel.

Case 2

Patient 2, male, 64 years old, was admitted to

hospital on December 1, 2020, due to "palpitation and shortness of breath after activity for 1 year, aggravating with chest pain for 2 months". Preoperative diagnoses were valvular heart disease with aortic insufficiency (severe), mitral insufficiency (moderate) and cardiac function II - III (NYHA grade), ascending thoracic aortic aneurysm, lipoma of chest wall, primary hyperthyroidism, and pulmonary tuberculosis (after treatment).

Surgical treatment was performed by Bentall operation and hemiarch replacement, mitral valvuloplasty and lipoma resection of the chest wall. The preparation and application of platelet gel was performed as above. The total amount of allogeneic platelets was 250 mL. The PG was used four times. When the left and right coronary arteries were transplanted with the artificial vessels, PG was sprayed on the surface twice. The thoracic aortic aneurysm wall wrapped on the artificial vessel and the site of pericardial suture were also sprayed with PG during the operation. The operation process went smoothly, and the intraoperative blood loss was about 800 mL.

About 220 mL and 250 mL PG were sprayed and painted on the two patients' aortic anastomosis site, aneurysm wall suture and cardiac incision (*Fig. 1-3*). The process of forming PG gel was extremely fast. After sprayed on the wound surface, it started to coagulate after 10 seconds. In about 20 seconds, a layer of transparent film like material could be seen. The area covered by gel had less oozing blood.

The blood group of patient 1 was AB RhD (+). The intraoperative blood loss was about 1 200 mL. The total liquid intake was 5 175 mL, including 1 825 mL crystal solution, 1 500 mL colloid solution, 400 mL suspended red blood cells, 600 mL fresh frozen

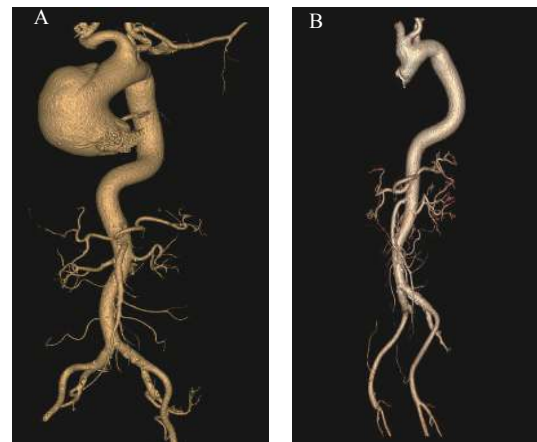


Fig. 1 The giant thoracic aortic aneurysm. Before (A) and after (B) operation on patient 1.

plasma and 10 U apheresis platelets. Approximately 650 mL red blood cells were recovered by extracorporeal circulation and reinfused.

The pericardial and the mediastinal drainage volumes were about 30 mL and 75 mL respectively,

in 24 hours after operation. On the second and third day after operation, 50 mL, 60 mL of mediastinal drainage and 60 mL, 20 mL of pericardial drainage were produced respectively (*Table 1*). The drainage tubes were pulled out on the 4th day after operation.

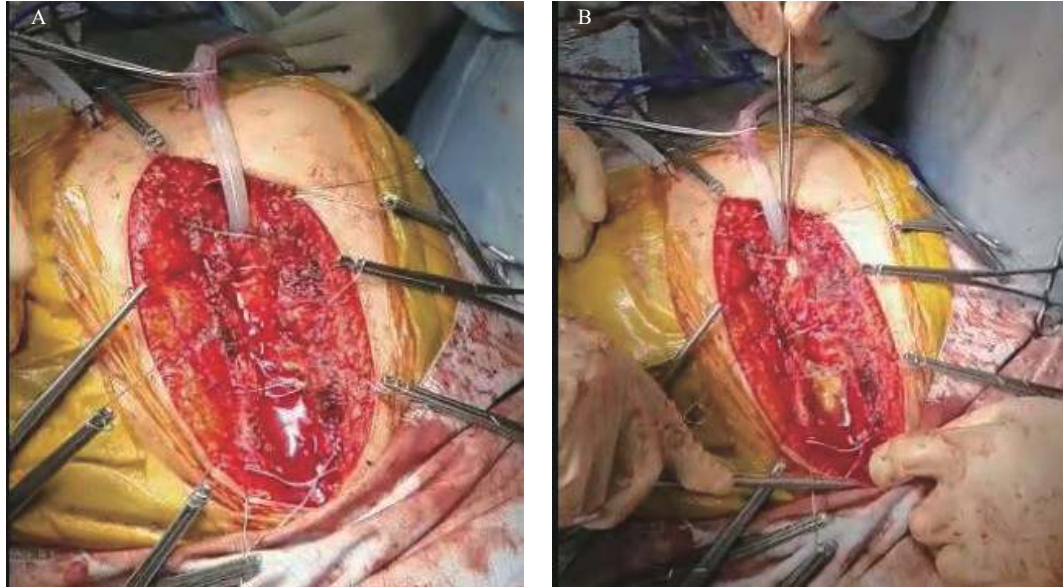


Fig. 2 The surface of chest wound at the 20th second (A) and the 90th second (B) after PG was sprayed on patient 1.

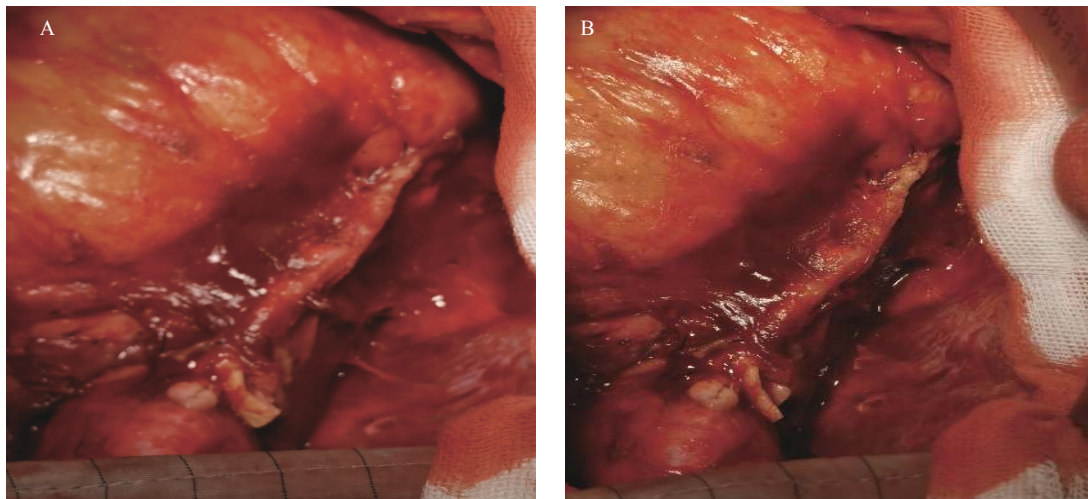


Fig. 3 The surface of thoracic aortic aneurysm wall wrapped on the artificial blood vessel at the 10th second (A) and the 30th second (B) after PG was sprayed on patient 1.

Table 1 The drainage change on the patients after operation

	Volume (mL)	After operation (d)			
		1 st d	2 nd d	3 rd d	4 th d
Case 1	Pericardial drainage	30	50	60	/
	Mediastinal drainage	75	60	20	/
Case 2	Pericardial drainage	590	220	120	80
	Mediastinal drainage	30	30	40	95

On the 5th day after operation, there were no complaints of unconsciousness, shivering, fever, palpitation, chest tightness and other discomfort. Then, the patient was transferred from ICU to a cardiothoracic surgery ward.

The blood group of patient 2 was O RhD (+), and the intraoperative blood loss was 800 mL. The total intake dosage was 4650 mL, including 2850 mL of crystal solution, 1500 mL of colloid solution, 400 mL of suspended red blood cells, and 400 mL of fresh frozen plasma. The drainage on the first, second, third and fourth day after operation were 590, 220, 120 and

80 mL for the pericardial drainage, and 30, 30, 40 and 95 mL for mediastinal drainage, respectively (*Table 1*). The drainage tubes were removed on the 5th day after operation. The patient's condition was normal on the 5th day and the patient was transferred from ICU to a cardiothoracic surgery ward.

The changes of blood routine tests and the four blood coagulation indexes were measured on patient 1 (*Fig. 4* and *Fig. 5*). The similar tests were also performed on patient 2.

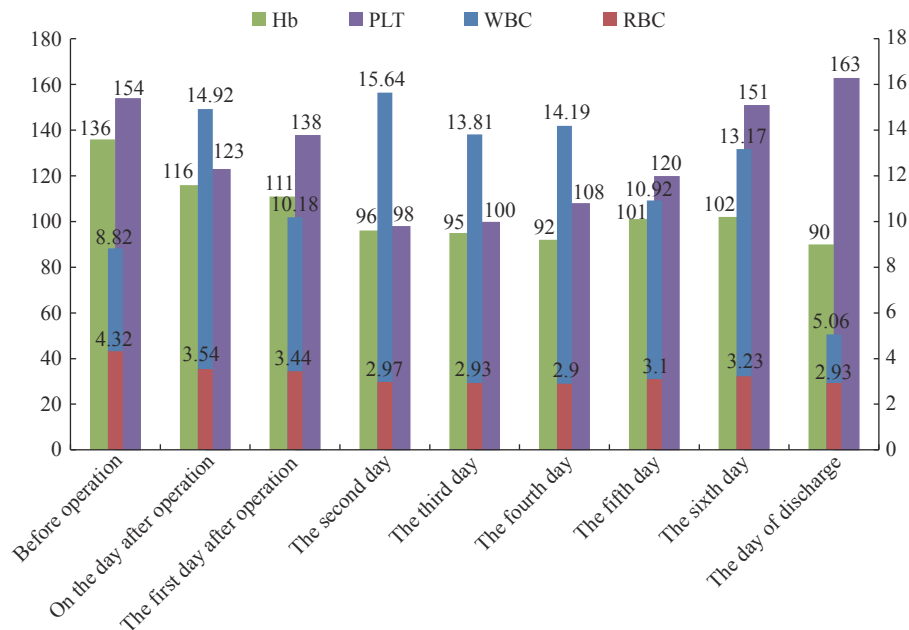


Fig. 4 The change of blood routine test (Hb g/L and PLT $\times 10^9/L$ on primary coordinates, WBC $\times 10^9/L$ and RBC $\times 10^{12}/L$ on secondary coordinates) on patient 1.

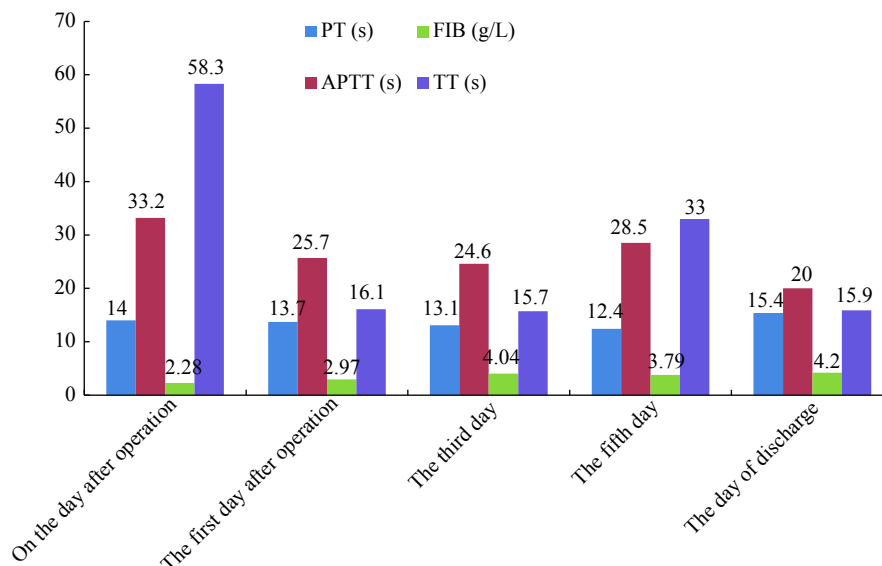


Fig. 5 The change of the four blood coagulation indexes on patient 1.

DISCUSSION

PRP and PG have been used in many clinical treatment fields because platelet concentrates contain a variety of growth factors. PRP or PG have been used mostly by autologous way. The qualified PRP or PG required platelet to reach 3–5 times count of the whole blood, and also to ensure sterility. Allogeneic PRP or PG was also used for surgical treatment. The safety and efficacy of allogeneic platelets have been confirmed^[6–10].

Allogeneic platelets were used as PRP to prepare PG. The PG was painted or sprayed on the anastomosis site of the blood vessel, suture of the tumor wall and wound site. The hemostatic effect of PG was clearly demonstrated, and also promoted wound healing. In general, the postoperative drainage fluid of the patients was up to more than 500 mL per day. The bleeding and drainage fluid were significantly reduced after PG application in both cases. On the first day after operation, patient 2 had more pericardial drainage fluid, more than 500 mL, but after 2 d the pericardial drainage fluid decreased day by day. The two patients were transferred out of ICU on the 5th day after operation. The drainage tubes were pulled out on the 4th and 5th day after operation respectively. The time in ICU was 2–3 days less than conventional patients without PG. The parameters of blood routine tests and the four blood coagulation indexes were measured postoperatively and tended to be normal on the day of discharge. As a result, the patients treated with PG also experienced reduced medical costs. The surgeons were very satisfied with the therapeutic effect of the massive dose PG used on the two patients.

Autologous PRP and PG have been widely used in clinics^[2–5]. In the majority of clinical experiments, clinicians have applied autologous platelets obtained by preoperative apheresis from the peripheral blood of the patient undergoing surgery. Some researchers show that the preparation of autologous platelet gel requires pre-operative apheresis, which adds the complexity, risk and cost of surgery^[11]. However, this may not always be the best solution. In cases of diabetes it has been shown that the release of platelet growth factors was decreased^[12]. Therefore, allogeneic PRP may benefit diabetic patients as a source of growth factors.

Currently, the surgical application of allogeneic PRP or PG is relatively infrequent, especially the use of a massive dose of PG. One reason is the difficulty in blood supply, another is the concerns of clinicians or patients about the safety of allogeneic platelets.

Despite the above, the use of allogeneic PRP or PG in the treatment of refractory bedsore, diabetic foot or bone defect repair has achieved good results at home and abroad^[6–12]. Allogeneic single donor platelets are easy to obtain, since they are a standard blood bank product. There are less immune rejection responses compared to porcine fibrin sealant, currently widely used in hospitals. They are highly standardized in terms of platelet content and the low counts of residual leukocyte and red blood cells. Balbo *et al* used small dose of allogeneic buffy coats (10 mL, concentrated platelets or PRP) and thrombin to prepare platelet gel, whereby 115 patients with finger amputations or wounds were treated with PG over 5 years, achieving positive outcomes^[7]. Also, allogeneic PRP or PG are available in large quantities and are considered safe. The allogeneic platelet concentrates from the blood bank are believed not to pose a significant risk for the patient. The results suggest that the use of allogeneic platelets should become popular in the clinical field, which could consequently positively impact blood banking policies.

In general, for PRP or PG use in clinic fields, the dosage is relatively small. We define that if the dosage of PRP or PG is less than 10 mL, it can be considered as a small amount of dose. A large or massive dose may reach 50 mL, or even more than 100 mL, while a medium dose is defined as 10–50 mL. The dosage of allogeneic PG of more than 200 mL was reported in this paper. This is the first report of a massive dose allogeneic PG clinical application on operation of giant thoracic aortic aneurysm. The use of massive dose allogeneic PG on surgical field would provide alternative method and technology for the clinical treatment.

References

- [1] Stolla M, Kapur R, Semple JW. New emerging developments of platelets in transfusion medicine[J]. *Transfus Med Rev*, 2020, 34(4): 207–208.
- [2] Rainys D, Cepas A, Dambrauskaite K, et al. Effectiveness of autologous platelet-rich plasma gel in the treatment of hard-to-heal leg ulcers: a randomised control trial[J]. *J Prescrib Pract*, 2020, 2(S8): 32–42.
- [3] Chicharro-Alcántara D, Rubio-Zaragoza M, Damiá-Giménez E, et al. Platelet rich plasma: new insights for cutaneous wound healing management[J]. *J Funct Biomater*, 2018, 9(1): 10.
- [4] Hom DB, Linzie BM, Huang TC. The healing effects of autologous platelet gel on acute human skin wounds[J]. *Arch Facial Plast Surg*, 2007, 9(3): 174–183.
- [5] Mazzucco L, Medici D, Serra M, et al. The use of autologous platelet gel to treat difficult-to-heal wounds: a pilot study[J]. *Transfusion*, 2010, 44(7): 1013–1018.

- [6] Jo CH, Lee SY, Yoon KS, et al. Allogeneic platelet-rich plasma versus corticosteroid injection for the treatment of rotator cuff disease: a randomized controlled trial[J]. *J Bone Joint Surg Am*, 2020, 102(24): 2129–2137.
- [7] Balbo R, Avonto I, Marenchino D, et al. Platelet gel for the treatment of traumatic loss of finger substance[J]. *Blood Transfus*, 2010, 8(4): 255–259.
- [8] Scevola S, Nicoletti G, Brenta F, et al. Allogeneic platelet gel in the treatment of pressure sores: a pilot study[J]. *Int Wound J*, 2010, 7(3): 184–190.
- [9] Wang ZR, Fan YH, Zhang H, et al. Clinical efficacy of allogeneic blood platelet rich plasma in refractory skin ulcer[J]. *J Clin Hematol*, 2018, 31(12): 895–897.
- [10] Smrke D, Gubina B, Domanović D, et al. Allogeneic platelet gel with autologous cancellous bone graft for the treatment of a large bone defect[J]. *Eur Surg Res*, 2007, 39(3): 170–174.
- [11] Calori GM, Tagliabue L, Gala L, et al. Application of rhBMP-7 and platelet-rich plasma in the treatment of long bone non-unions: a prospective randomised clinical study on 120 patients[J]. *Injury*, 2008, 39(12): 1391–1402.
- [12] Tian J, Lei XX, Xuan L, et al. The effects of aging, diabetes mellitus, and antiplatelet drugs on growth factors and anti-aging proteins in platelet-rich plasma[J]. *Platelets*, 2019, 30(6): 773–792.
- Received 25 February 2021, Revised 24 March 2021, Accepted 22 April 2021**

MANUSCRIPT SUBMISSION

Manuscripts are submitted via our Online Editorial System at <http://www.blood-genomics.com/>

